

The Cleveland Clinic experience with adult hypospadias patients undergoing repair: their presentation and a new classification system

Christina B. Ching, Hadley M. Wood, Jonathan H. Ross*, Tianming Gao[†] and Kenneth W. Angermeier

Cleveland Clinic Foundation, Glickman Urological and Kidney Institute, *University Hospitals Case Medical Center, Rainbow Babies & Children's Hospital, and [†]Cleveland Clinic Foundation, Quantitative Health Sciences, Cleveland, OH, USA

Accepted for publication 7 May 2010

Study Type – Therapy (case series)
Level of Evidence 4

OBJECTIVE

- To characterize and categorize adults with hypospadias who presented to our clinic with urethral stricture and fistula to better clarify the presentation, history and intraoperative findings in this heterogeneous group and to better describe the natural history of this anomaly in adulthood.

PATIENTS AND METHODS

- A retrospective chart review was performed on adults with hypospadias who underwent urethroplasty for urethral stricture, urethrocutaneous fistula, and/or hypospadias repair at Cleveland Clinic between 1993 and 2009. All procedures were performed by a single staff surgeon (K.W.A.).
- The charts were reviewed for site of hypospadias, presenting complaint, overall symptoms, history of repair and type of surgery performed.

RESULTS

- Fifty-five adult patients were identified. Median age was 37 years (range: 18–72).
- About half of the patients had distal (glanular/subcoronal or pendulous)

What's known on the subject? and What does the study add?

Most previous studies, with few exceptions, have focused on short-term outcomes of hypospadias repair in infancy or young adulthood. Little is known, however, about the long-term outcomes both after hypospadias repair in childhood and for uncorrected hypospadias into adulthood. We report how these patients present to a urologist and their concurrent symptoms and add a classification system of how these patients present for urethral stricture/fistula/hypospadias repair.

hypospadias (56.4%) and the others had more proximal (bulbar) hypospadias (43.6%).

- Voiding symptoms (such as dysuria, weak stream, spraying, urgency, frequency) were the most common presenting complaint (50.9%) and overall symptom (81.8%). About half of patients underwent a two-stage urethroplasty (52.7%).
- Based on their history of repair, patients were divided into three categories: I, patients who have undergone continuous multiple surgeries for repair with significant scarring and tissue loss; II, delayed complications after an initially successful childhood repair; and III, no previous repair. Most patients were category I (58.2%); however, seven patients (12.7%) were category III. Balanitis xerotica obliterans (BXO) was more common in this subgroup compared with other categories (42.9% vs 8.3%, respectively, $P = 0.037$). In two of the three patients in category III with BXO, the stricture length was longer than 7 cm.

CONCLUSIONS

- Adults with hypospadias represent a heterogeneous group. More than half of

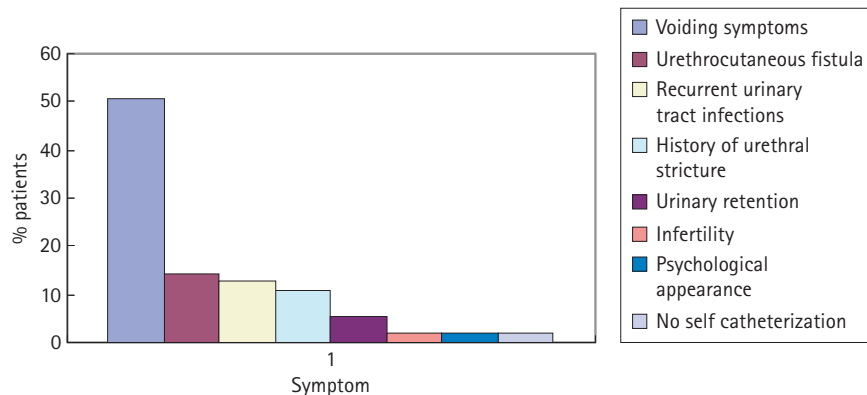
adults with complications related to hypospadias have had multiple operations (category I) representing one of the most difficult challenges to the reconstructive urologist.

- Roughly 30% of patients undergo an initially successful repair in childhood with recurrent problems in adulthood (category II), suggesting that the outcomes of repair may not be as durable as estimated by studies with shorter-term follow-up.
- Finally, BXO is over-represented in men with hypospadias who have not previously undergone repair, which contradicts the previous suggestion that the risk of BXO is related to the use of skin grafts/flaps from previous repairs and suggests that there may be an increased risk of severe stricture disease in patients who have never undergone corrective surgery for this anomaly.

KEYWORDS

adult hypospadias, urethroplasty, classification, long-term outcomes, balanitis xerotica obliterans

FIG. 1. Initial presenting complaint.



INTRODUCTION

There is much literature about the paediatric patient with hypospadias; the long-term follow-up and sequelae of these repairs into adulthood, however, is difficult to track and has been underemphasized. One of the largest studies was done by Bracka [1], looking at the long-term psychological and physical sequelae of 213 patients who had undergone previous hypospadias repair over a 30-year period. He found that patient education and long-term follow up were imperative for patient satisfaction, advocating that patients need to be followed at least until maturity. He also stressed the importance of cosmesis, reporting that 72% of his patients felt that a phallus of normal appearance was as important as one that was functionally appropriate.

Traditionally, the goals of hypospadias repair have included three key factors: a cosmetically normal phallus; the ability to urinate in a standing position; and good sexual function [2,3]. Hypospadias surgery requires fine surgical skills, which is emphasized by the fact that urologists and plastic surgeons alike are known to perform the reconstruction. The success of a repair can be credited to good tissue and vascular supply [3–5], which may be intricately related to patient age and the number of operations a patient has undergone. The rate of hypospadias repair complications ranges from 10.1 to 37.5% in adult patients undergoing a first-time repair but more than doubles to between 27.5 and 63.6% [2,6] in patients with at least one previous repair attempt.

We reviewed our experience with adult hypospadias patients to identify key

characteristics of this population. We wanted to determine what issues these patients face: how these patients present, what symptoms they experience, and the extent of their surgical history. We also wanted to see what trends may arise within this heterogeneous group such as the timing of complications and number of previous repairs. Importantly, we also wanted to know what issues may arise in adulthood for the patient who remains unrepaired.

MATERIALS AND METHODS

We performed a retrospective, Institutional Review Board-approved, chart review of adults with hypospadias who underwent urethroplasty for urethral stricture, urethrocutaneous fistula and/or hypospadias repair between 1993 and 2009. All procedures were performed by a single staff surgeon (K.W.A.). The charts were reviewed for site of hypospadias or first location of 'normal' healthy bulbospongiosus noted at the time of urethral reconstruction, presenting complaint, overall symptoms, type of surgery performed and history of repair. Outcome after surgery was not evaluated in this review given that the objective of this investigation was to describe the population, not surgical outcomes.

Based on their history of repair, the patients were divided into three categories: I, patients who have undergone multiple surgeries for repair throughout their lives with significant resulting scarring and tissue loss; II, delayed failure after childhood hypospadias repair with subsequent issues only in adulthood; and III, no previous repair. Level of 'normal' or healthy urethra was determined upon review

of operative dictation noting first sight of healthy, intact bulbospongiosus. As the hypospadias phenotype is defined by a lack of bulbospongiosus at the distal-most aspect of the urethra, this characterization probably estimates the level of hypospadias to be more proximal than reports that rely on location of the urethral meatus. None the less, this characterization is consistent and not dependent on co-existing chordee.

The review consisted of looking for documentation in the history and physical examination, pathology report and operative dictation of anatomy, complaints/symptoms and diagnoses. To compare the incidence of our findings we used a Fisher's exact test secondary to the small sample sizes.

RESULTS

Fifty-five adult patients underwent urethroplasty at our institution for primary hypospadias or complications after previous hypospadias repair between 1993 and 2009. Median patient age was 37 years (range: 18–72). About half (56.4%) of the patients had distal (penile shaft or glanular/subcoronal) hypospadias. The rest had more proximally located hypospadias in the bulbar urethra.

The most common presenting complaint (incidence 50.9%) was voiding symptoms, including dysuria, stream spraying, straining, sense of incomplete emptying, weak stream, frequency and urgency. Urethrocutaneous fistula (UCF) from previous hypospadias repair was the second most common initial presentation (14.5%); recurrent UTIs was the third (12.7%) (Fig. 1). Voiding symptoms were also the most common overall symptoms reported (81.8% of patients), whereas UCF was only present in 16.4% of patients overall. Chordee was present in 23.6% of patients and penoscrotal webbing or transposition was present on examination in 5.4%. Other congenital anomalies such as history of an undescended, ectopic, dysgenetic, or ovarian gonad was present in 14.5% of patients. Mixed gonadal dysgenesis, ambiguous genitalia and an imperforate anus/solitary kidney were each found in one patient (1.8% each). Five patients (9.1%) had a history of documented infertility or hypogonadism and erectile dysfunction was reported in 7.3% of patients. Balanitis xerotica obliterans (BXO) was present in 12.7% of patients based on physical examination and operative or pathology report (Table 1).

TABLE 1 Overall patient symptoms

Symptom	n (%)
Voiding symptoms: dysuria, spraying, urgency, etc.	45 (81.8)
Recurrent urinary tract infections	20 (36.4)
Chordee	13 (23.6)
Infertility/undescended testicle (UDT)	13 (23.6)
Infertility/hypogonadism	5 (9.1)
UDT/dysgenetic testicle/ovarian gonad/ectopic testicle	8 (14.5)
Acute urinary retention	11 (20.0)
Urethrocutaneous fistula	9 (16.4)
Balanitis xerotica obliterans	7 (12.7)
History of urethral stricture	6 (10.9)
Incontinence	5 (9.1)
Erectile dysfunction	4 (7.3)
Penoscrotal web/transposition	3 (5.4)
Meatal stenosis	1 (1.8)
Mixed gonadal dysgenesis	1 (1.8)
Ambiguous genitalia	1 (1.8)
Imperforate anus/solitary kidney	1 (1.8)
Psychological impact of penile appearance	1 (1.8)
Did not want to self-catheterize	1 (1.8)

Roughly half of patients were planned as two-stage urethroplasties (52.7%). All but two of the patients have actually undergone both stages; one patient awaits scheduling for his second stage and another has elected not to proceed with his second stage because of complete satisfaction after only his first stage of repair. Two patients also required revisions, one for removal of redundant buccal mucosa and the other for closure of a previous perineal urethrostomy. Perineal urethrostomy was performed in 21.8% of patients either because the patient was medically unfit or their disease was too severe for a formal complete urethroplasty or secondary to patient preference (Table 2).

We found that patients fit into three categories: I, patients who have undergone more than two urethral reconstructions with resulting penile deformity, tissue loss and significant scarring with persistent problems; II, patients experiencing late failure in adulthood after an initially successful childhood repair; and III, hypospadias patients who have never been repaired. Most of our patients presenting for repair were category I (32 patients or 58.2%) while 29.1% represented late failures (category II) (Fig. 2).

TABLE 2 Type of urethroplasty repair

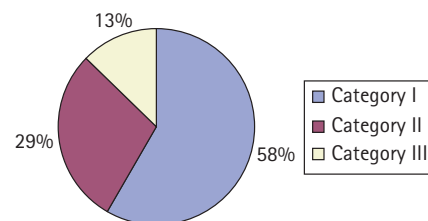
Type of repair	n (%)
Two-stage	29 (52.7)
Alone	23 (41.8)
With plication	2 (3.6)
With revision	2 (3.6)
One-stage only so far	2 (3.6)
Perineal urethrostomy	12 (21.8)
One-stage	14 (25.5)
Alone	13 (23.6)
With scrotoplasty	1 (1.8)

Seven patients (12.7%) had never been repaired, comprising category III. Six of them presented with voiding symptoms as described previously. One patient presented with infertility. Interestingly, none of the patients presented secondary to cosmetic appearance. Four of the patients in category III were able to undergo a single-stage urethroplasty, while two of the patients underwent a two-stage urethroplasty and one patient underwent perineal urethrostomy. Three patients were diagnosed with BXO based on pathology report or office examination, which was significantly higher than the incidence of BXO in the other categories (42.9% vs 8.3% respectively, $P = 0.037$). Four patients in this category were noted to have chordee in their examination or history, which was also significantly higher than the incidence of chordee in the other categories (57.1% vs 18.8% respectively, $P = 0.046$). Curvature of erections, however, was not the presenting complaint for any patient in category III.

DISCUSSION

There is much to suggest that hypospadias in adult life is different from hypospadias in childhood. Adolescent or adult hypospadias patients are much more likely to have undergone at least one previously attempted repair with subsequent distortion of anatomy and vasculature. In a large study by Bracka [7], roughly one-third of patients were 'salvage' or had undergone previous attempted repair, with one-quarter of the patients being adults or adolescents. As a result, these patients tend to have a higher rate of complications, ranging between 12.4 and 48% [8,9] than those repaired in infancy, 3.4% [10]. Even in primary repair, the adult patient has different issues that may affect overall surgical success

FIG. 2. Category system for adult hypospadias patients.



such as different skin and hair flora that may introduce infection and poor wound healing, nocturnal or volitional erections that can impair graft take as well as cause postoperative bleeding and dehiscence [6,11], and an increasing incidence of co-morbidities that may dictate surgical approach and postoperative care [8].

Only relatively recently has there been interest in defining the adult hypospadias patient population and documenting the issues that are unique to this group. Lam *et al.* [12] performed a review of operative complications an average of 13 years after two-stage urethroplasty in infancy for severe hypospadias and chordee. They found that only two of 27 patients had complications after adolescence whereas most complications occurred an average of 1–2 years after the initial repair. Our experience, however, shows that late complications can and do occur, confirming the sentiments of Bracka [1] that follow up of childhood hypospadias repair should at least continue until maturity.

Most adult patients with hypospadias presenting to our practice with issues related to voiding or sexual dysfunction and who ultimately need repair are those who have already had multiple previous repairs with continuing complications, primarily related to stricture disease (manifest by voiding symptoms). Not surprisingly, UCF was the second most common presenting complaint in our group, probably because of the number of their previous operations, the types of donor materials used in earlier reconstructions, and associated poor tissue quality. Bracka [13] reported a 10.5% rate of UCF in patients undergoing salvage hypospadias repair versus a 3% rate in those undergoing a primary repair. In the past, UCF was believed to only occur in the immediate postoperative period. Our finding that 16.4% of our patients had a

UCF corroborates previously published literature showing a bimodal distribution for this complication [14].

Persistent chordee after hypospadias repair can either be from uncorrected chordee during the initial repair or fibrosis of the repair [15]. We found that it was the third most common overall symptom in our patients. In the series by Secrest *et al.* [15] of 177 patients treated for previous hypospadias repair complications, 71 patients presented with chordee. Gershbaum *et al.* [16] reported recurrent chordee in 22% of patients after single-stage urethroplasty for hypospadias and Nesbit procedure for chordee correction, although Lam *et al.* [12] reported no residual chordee in 27 patients an average of 13 years after undergoing two-stage urethroplasty in infancy for severe hypospadias and chordee.

Cosmetic dissatisfaction in men with hypospadias has been reported to be as high as 25–44% [1], with 84.7% of men perceiving a difference in how their genitalia appear compared to men without hypospadias [17]. Bracka [1] reported that 38% of adolescent/adults 'still felt deformed' with 44% requesting surgical revision. In our group, only one patient presented with actual dissatisfaction of penile appearance and another patient presented with dissatisfaction about management of his voiding issues (unwilling to self-catheterize anymore). Similarly, in a review of 56 adult men with uncorrected hypospadias, Dodds *et al.* [18] found that only three men (5%) were dissatisfied with the appearance of their penis. Interestingly, none of the men expressing discontent had undergone previous attempted repair and did not include men noted objectively by physicians to have 'substantial scar formation' from previous repair.

The patients comprising category III in our study serve as a model for patients with uncorrected hypospadias as they become adults. Repair of hypospadias in childhood is advocated to avoid the cosmetic and functional consequences that can arise as a sequelae of the anomaly, such as sitting to void, urine spraying, the psychological impact of penile appearance and infertility secondary to abnormal position of urethral meatus [18]. In our series, no patient reported psychological sequelae of the cosmetics of their uncorrected hypospadias. In fact, voiding

symptoms were the main complaint, although we also found a significantly higher risk of chordee (four patients) and BXO (three patients) in this subgroup in comparison with the other categories. Probably as a result of their BXO, these patients were also at risk for more severe stricture disease; three of the patients had stricture disease >3.5 cm with two patients having strictures of 7 and 8 cm of length. We feel that these risk factors should be included when counselling patients' parents in the paediatric urologist's office. The over-representation of BXO in this subgroup also contradicts the previous suggestion that BXO in the adult hypospadias patients is a phenomenon related to use of skin-containing donor materials [13] used in reconstruction because none of these patients had undergone previous reconstruction.

The key to properly counselling and treating adult patients with hypospadias is to understand the progression of the disease. Bracka [1] performed one of the earliest and largest reports looking at long-term sequelae of hypospadias repair. He evaluated the psychological and anatomical outcome of 213 patients repaired over 30 years. Importantly, he found that one of the biggest contributors to adolescent/adult dissatisfaction from previous childhood repair was lack of understanding or ignorance about their deformity. He also found that the common act of releasing patients from regular follow-up 1–2 years postoperatively was inadequate with 74% of patients saying they received inadequate guidance.

Unfortunately, the adult hypospadias patient does not appear to fit any one mould. They are as diverse as the location of hypospadias itself, varying from those unaware that they even have an abnormality [18] to those who in the past have been termed 'cripples'. As a result, it would be extremely useful to have a classification system to give some direction to patients as to future expectations as well as to give some guidance to the urologist as to which repair may work best. A universal classification system may also help to standardize reporting in future literature and in studies performed on the subject. Previously, Secrest *et al.* [15] made a group system based on difficulty of procedure required for correction. A benefit of our system is that it is based on patient history and so acts as an education and counselling tool before the patient even undergoes surgery.

It should be noted that the location of hypospadias used in our system was based upon operative findings at the time of urethroplasty and not initial hypospadias diagnosis. Unfortunately, many of the patients in our study were outside referrals and had undergone previous intervention or work-up at outside institutions so we had little information on initial meatal location. As a result, and as a way of standardizing the anatomy, we used the location of first healthy corpus spongiosum noted in the operative dictation to be the location of hypospadias. Our classification of hypospadias location is therefore based on urethral anatomy (often after previous operations, including correction of chordee) and not the traditional definition of hypospadias by meatal location. As a result, we probably overestimate how proximal the initial meatal location was. This may make our findings difficult to interpret in and apply to the patient whose meatal location is known. It must also be remembered that the procedures they may have undergone reflect 20–30 years of progress and may incorporate what would now be considered inferior techniques. The outcomes of these procedures might not be reflective of outcomes from current techniques or standards of care.

Another limitation of our study was that this was a chart review and so was limited by the completeness of documentation. We diagnosed patients with BXO and chordee based on documented findings on examination or operative or pathological report. Unfortunately, if something was not completely documented it could have been erroneously missed.

It is also important to note that all of these patients ultimately underwent urethral repair. These patients represent the extreme end of the spectrum of adults with hypospadias with complications that require surgical intervention. We did not have a base or control group of adult males with hypospadias that had been previously repaired without complication with which to compare these patients. The only patients we saw were those affected and having symptoms from their hypospadias undergoing subsequent urethroplasty or perineal urethrostomy. As a result, their presentations may be biased towards issues that would require surgical intervention versus those that could have been managed conservatively or endoscopically.

Hypospadias repair has the highest chance of success with the initial repair, with an increasing risk of complications with subsequent procedures. Unfortunately, most adult patients presenting in the adult urologist's office undergoing urethroplasty or perineal urethrostomy have undergone multiple previous failed repairs. In our series, most of these patients must undergo two-stage repairs or even perineal urethrostomy as a last resort. A small percentage of patients, however, have previously unrepaired hypospadias, with roughly a 50% risk of having BXO and a high chance of severe stricture disease. Regardless, we feel strongly that this complicated subset of patients requires special surgical attention at a centre with a surgeon who is comfortable with and knowledgeable about these issues.

ACKNOWLEDGEMENTS

This project was supported by departmental resources only.

CONFLICT OF INTEREST

None declared.

REFERENCES

- 1 Bracka A. A long term view of hypospadias. *Br J Plast Surg* 1989; **42**: 251–5
- 2 Senkul T, Karademir K, Iseri C, Erden D, Baykal K, Adayener C. Hypospadias in adults. *Urology* 2002; **60** (6): 1059–62
- 3 Retik AB, Atala A. Complications of hypospadias repair. *Urol Clin North Am* 2002; **29** (2): 329–39
- 4 Snodgrass W, Koyle M, Manzoni G, Hurwitz R, Caldamone A, Ehrlich R. Tubularize incised plate hypospadias repair: results of a multicenter experience. *J Urol* 1996; **156**: 839–41
- 5 Ross JH, Kay R. Use of a de-epithelialized local skin flap in hypospadias repairs accomplished by tubularization of the incised urethral plate. *Urology* 1996; **50** (1): 110–2
- 6 Hensle TW, Tennenbaum S, Reiley EA, Pollard J. Hypospadias repair in adults: adventures and misadventures. *J Urol* 2001; **165**: 77–9
- 7 Bracka A. Hypospadias repair: the two-stage alternative. *Br J Urol* 1995; **76** (3): 31–41
- 8 Dodson JL, Baird A, Baker LA, Docimo SV, Mathews RI. Outcomes of delayed hypospadias repair: implications for decision making. *J Urol* 2007; **178** (1): 278–81
- 9 Li LC, Zhang X, Zhou SW, Zhou XC, Yang WM, Zhang YS. Experience with repair of hypospadias using bladder mucosa in adolescents and adults. *J Urol* 1995; **153**: 1117–9
- 10 Marrocco G, Vallasciani S, Fiocca G, Calisti A. Hypospadias surgery: a 10 year review. *Pediatr Surg Int* 2004; **20** (3): 200–3
- 11 Baran CN, Tiftikcioglu Y, Ozdemir R, Baran NK. What is new in the treatment of hypospadias? *Plast Reconstr Surg* 2004; **114** (3): 743–52
- 12 Lam PH, Greenfield S, Williot P. 2-stage repair in infancy for severe hypospadias with chordee: long-term results after puberty. *J Urol* 2005; **174** (4 Pt 2): 1567–72
- 13 Bracka A. A versatile two-stage hypospadias repair. *Br J Plast Surg* 1995; **48**: 345–52
- 14 Wood HM, Kay R, Angermeier KW, Ross JH. Timing of the presentation of urethrocutaneous fistulas after hypospadias repair in pediatric patients. *J Urol* 2008; **180**: 1753–6
- 15 Secrest CL, Jordan G, Winslow BH *et al*. Repair of the complications of hypospadias surgery. *J Urol* 1993; **150**: 1415–8
- 16 Gershbaum MD, Stock JA, Hanna MK. A case for 2-stage repair of perineoscrotal hypospadias with severe chordee. *J Urol* 2002; **168** (4 Pt 2): 1727–8
- 17 Mureau MA, Slijper FM, Slob AK, Verhulst FC, Nijman RJ. Satisfaction with penile appearance after hypospadias surgery: the patient and surgeon view. *J Urol* 1996; **155**: 703–6
- 18 Dodds PR, Batter SJ, Shield DE, Serels SR, Garafalo FA, Maloney PK. Adaptation of adults to uncorrected hypospadias. *Urology* 2008; **71** (4): 682–5

Correspondence: Kenneth W. Angermeier, Cleveland Clinic Foundation, Glickman Urological and Kidney Institute, Cleveland, Ohio, USA.
e-mail: angermk@ccf.org

Abbreviations: BXO, balanitis xerotica obliterans; UCF, urethrocutaneous fistula.