

Reconstructive penile surgery: a review

G. Liguori, A. Amodeo, B. Deconcilio, S. Benvenuto, R. Napoli, G. Ollandini, G. Mazzon, C. Trombetta, E. Belgrano

Department of Urology, University of Trieste, Italy

Key words

Penis • Surgery • Peyronie's disease • Penile carcinoma • Phalloplasty • Erectile dysfunction

Summary

A variety of surgical procedures have been described to treat various penile diseases.

Nowadays the purpose of all surgical techniques in penile surgery is not only the correct treatment of the primary condition, but also to preserve sexual function and to maintain cosmesis of the penis. Appropriate treatment options should be individualized according to the patients' expectations and erectile capacity.

The present paper reviews recent advances in the field of penile reconstructive surgery using knowledge obtained from the contemporary literature.

Introduction

This article provides an overview of the current concepts in reconstructive surgery following penile cancer, congenital and acquired deformity and erectile dysfunction. It covers the initial management of these diseases, with the aim of preservation of as much viable tissue as is practical, and also provides advice on dealing with penile avulsion and amputation injuries.

Besides the anatomical and histological studies of the penis, major contributions have been described in congenital and acquired penile anomalies. Also, a few new techniques and modifications of old procedures are described in order to improve the final functional and aesthetic outcome. Finally, penile cancer management is reviewed, from initial biopsy to definitive treatment of the penile lesion-including wide excision, partial glansectomy, total glansectomy, and partial and total penectomy. It is concluded that appropriate surgery in all these conditions reduces subsequent long-term problems in sexual function, cosmesis, psychology, and (in cancer cases) longevity. The same reconstructive techniques can be applied for different penile conditions, and it is suggested that surgeons become experienced in genital surgery as a whole, rather than in oncology or trauma alone.

Methods

A critical non-structured review of the literature regarding the surgical treatment alternatives for penile reconstructive surgery was constructed.

Corresponding author:

Giovanni Liguori, Department of Urology, University of Trieste, strada di Fiume 447, 34144 Trieste, Italy – Tel. +39 040 399 4096 – Fax +39 040 399 4895 – E-mail: gioliguori@libero.it

We matched key words throughout Medline, MeSH and Cochrane databases: penis, surgery, Peyronie's disease, penile carcinoma, phalloplasty, erectile dysfunction.

Results

Penile cancer surgery

Penile cancer is a rare tumour in Europe with an incidence of 1 per 100,000 men per year ¹. It is most commonly diagnosed in the sixth and seventh decades of life but can occur at any age, including childhood. Throughout the world penile carcinoma occurs more frequently in societies where hygiene is poor or where circumcision is not routinely practiced: as a matter of fact indirect evidence support a carcinogenic effect of smegma, whose accumulation is favoured by poor hygiene and phimotic foreskin ². Moreover there is strong evidence that HPV types 16 and 18 are associated with penile carcinoma in as many as 50% of cases, as well as with penile carcinoma in situ, and basaloid and warty verrucous varieties in more than 90% of cases.

Squamous cell carcinoma (SCC) is by far the most common malignant disease of the penis, accounting for more than 95% of cases. Malignant melanomas and basal cell carcinoma are less common. Although SCC is the most common penile cancer, it manifests in several different types and with varying growth patterns ³.

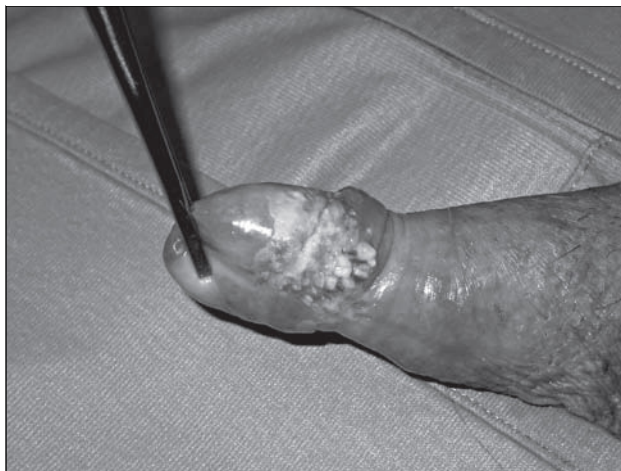Mesenchymal tumours are very uncommon, with an incidence rate of less than 3% (e.g. Kaposi's sarcoma, angiosarcoma, epithelioid haemangioendothelioma).

The penis is a very rare metastatic site, but bladder, prostate, renal and rectal tumours have been reported as primary tumours in cases of metastatic disease ⁴.

In case of penile cancer, imaging is generally not needed for diagnosis because the tumor is usually visible at physical examination. The main purpose of penile imaging is to evaluate the degree of infiltration of the corpora cavernosa and for staging purpose. As a matter of fact, in stage I tumor the cancer is limited to the glans and the foreskin, not involving the corpora: in these cases penis-preserving surgical treatment should be offered.

Tumors involving the foreskin may be treated by circumcision alone, and lesions involving the glans or shaft may be treated by local wedge excision, unfortunately, local recurrence may occur in up to 50% of patients ⁵. Traditionally standard therapy requires

Figure 1. In this case the lesion involved the penis and the distal shaft.



excision of 2 cm of penile shaft proximally to the extent of the tumour ⁶.

For lesions involving the glans and distal shaft (Fig. 1), partial penectomy should leave a residual penile stump suitable for upright micturition and sexual function. Involvement of the proximal shaft requires total penectomy. Extension to the perineum, pubis or scrotum in the absence of metastatic disease may require more extensive resection and adjuvant chemotherapy.

Although radical surgery gives excellent control of the primary tumour, it is mutilating and probably unnecessary in case of low-grade and low-stage tumours ⁷. In these cases conservative techniques (laser therapy, cryotherapy, photodynamic therapy, topical 5-fluorouracil, or local excision (glansectomy) and reconstruction) give better cosmetic and functional results ⁸.

As a matter of fact, it is still unknown what excision margin is required to achieve local control after surgery for penile cancer and recent evidence, however, has suggested that margins of only a few millimetres may be adequate for most tumours, which has led to increasing interest in penile-preserving procedures ⁹.

Current European Association of Urology (EAU) guidelines on the management of penile cancer strongly recommend a penile-preserving approach for patients with Ta-T1 G1-G2 tumours who can commit to a regular surveillance programme, and the guidelines suggest that it may also be an option in very selected patients with T1 G3 and T < 2 disease whose tumours occupy less than 50% of the glans ⁸.

In a recent review of 20 years of penile cancer therapy McDougal shows that survival is improving whilst the surgery is becoming more conservative ¹⁰.

In another recently published paper, Minhas showed that the conventional 2 cm margin of resection is not necessary for oncological control. In 51 patients, 48% had margins of less than 1cm and 90% less than 2 cm. Only two local recurrences were found only in the high-grade tumours¹¹. Hoffman examined pathological resection margins of patients undergoing partial or total penectomy and found no local recurrences in any of their 14 patients, despite seven having resection margins < 10 mm. Average follow-up was 33 mo for patients who had partial penectomy and 40 mo for the total penectomy group⁹. Smith described 72 patients who underwent glansc-tomy with reconstruction for glans-confined penile squamous cell cancer. Local disease control has been excellent, with a 6% recurrence rate, despite 24 patients (33%) having high-grade tumours and 37 (51%) with T2 disease¹².

In conclusion in the last years management of the primary tumour has moved towards conservative surgery and recurrence rates seem to be extremely low; however longer follow-up studies are required to further assess this.

Erectile dysfunction surgery

Erectile dysfunction (ED) is defined as the consistent inability to achieve or maintain penile erection satisfactory for sexual intercourse. It is estimated that some form of erectile dysfunction will develop in 52% of men between ages 40 and 70 years¹³.

Non-surgical treatment alternatives for ED include psychological, endocrinological, neurological and pharmacological therapy, including oral, topical and intraurethral delivery agents, and external device modalities¹⁴.

Moreover advances in the treatment of erectile function, notably the introduction of Sildenafil in 1997, have increased public awareness of the disorder and the number of men seeking treatment.

For patients in whom none of these therapies have proved to be successful, a variety of surgical procedures have been developed during the years¹⁵. Surgical interventions have consisted primarily of penile prosthesis insertion and arterial bypass surgery. Venous leakage surgery for corporeal veno-occlusive dysfunction came later in the mid 1980s to early 1990s¹⁶.

Penile prosthesis implantation

Penile prosthesis implantation is commonly accepted like an effective surgical option for treatment of severe vascular erectile dysfunction; moreover more than 90% of patients report satisfaction with the

prostheses. However, according to most guidelines for erectile dysfunction penile prosthesis implantation remains the third choice for therapy after failure of other less invasive therapeutic options^{17, 18}.

Penile revascularization in vasculogenic post-traumatic impotence is a very useful urological tool, but correct selection of the patients is mandatory. The ideal candidates for this kind of surgery are young men with no significant vascular risk factors and whose impotence can be related to arterial lesions of the pudendal, common penile or cavernous arteries due to pelvic bones fractures or blunt perineal trauma¹⁹. The presence of a concurrent traumatic veno-occlusive dysfunction following blunt pelvic or perineal trauma is not a rare finding²⁰. The presence of traumatic corporeal veno-occlusive dysfunction would affect patient prognosis unfavourably in bypass surgery, since there appears to be no obvious long term benefit for surgical intervention in the presence of veno-occlusive dysfunction. The patients with significant vascular risk factors are poor candidates for by-pass surgery and are encouraged to consider other options for treating their impotence.

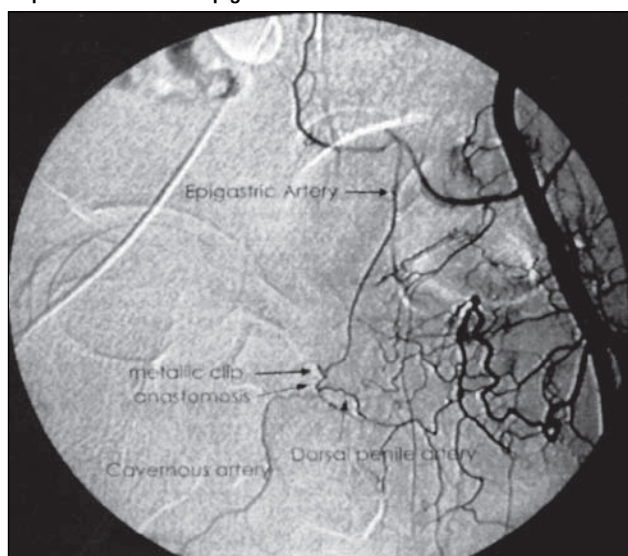
Various penile revascularization techniques have been described in the last twenty years, but in our opinion each of them should be personalized depending on the pathological findings encountered in each single case. In addition, preference should be given to physiological revascularization procedures whenever possible. Series published in the past 10 years have used a variety of procedures. Long term successful results in these studies, with admittedly varied patient populations, indications and techniques have ranged from 25 to 80%²¹.

In our opinion, the anastomosis according to the Sharlip technique is the best solution because it envisages a retrograde revascularization of the cavernous artery through the common penile trunk. For this reason we usually anastomosed the epigastric artery on the dorsal artery of the penis end-to-end in the proximal direction (Fig. 2). This technique has been associated with the most success and the fewest complications¹⁷.

Penile venous surgery

In selected cases, patients with venous leak impotence can be treated by penile venous dissection and ligation. Penile venous resection decrease the number of channels for venous outflow from the penis and, therefore, increases venous resistance improving erections. Many published series show an important improvement at short time follow-up but a poor result at long term follow-up²²⁻²⁷. Several differ-

Figure 2. Postoperative selective internal iliac arteriography reveals the patency of the microvascular anastomosis. A metallic clip is visible on the epigastric vein near the anastomosis.



ent factors can account for the important failure rate of penile venous surgery. Inability to accurately diagnose concomitant arterial disease and less extensive venous dissection, probably account for many of the early patient failure. With the use of stricter diagnostic inclusion criteria and a more aggressive surgical approach, many of these early failure could have been avoided. The development of collateral venous circulation is the most likely cause of late failure. Finally another reason for failure is that ligation of penile veins may not address the true underlying pathologic disorder in many patients which is sinus smooth muscle disease that prohibits the expansion of the tunica albuginea.

Reconstructive phallic surgery

Phalloplasty is considered to be one of the most challenging procedures in reconstructive surgery. The development of techniques of phalloplasty has paralleled the evolution of flap development in reconstructive surgery itself. Initially, random tubed pedicled flaps were used. Subsequently, pedicled island flaps and myocutaneous flaps have been applied. With the development of the microsurgical techniques, free flaps also were introduced in phalloplasty. In his review of surgical techniques Hage reports that for reconstruction of the phallus in non-transsexual men a variety of techniques have been suggested or used, including bipediced single abdominal flaps, bipediced tube-within-tube flaps, infraumbilical pedicled flaps, scrotal flaps, groin flaps, thigh flaps, pedicled myocutaneous gracilis

flaps²⁸, pedicled myocutaneous rectus abdominis flaps²⁹, free microsurgical forearm flaps³⁰ and free microsurgical upper arm flaps³¹.

For phalloplasty in female-to-male transsexuals the following techniques have been described: Bogaras bipediced abdominal tabularised flaps³², Maltz-Gillies tube-in-tube bipediced flaps³³, Stanford inside-out infraumbilical flaps³⁴, subcutaneous pedicled infraumbilical flaps³⁵⁻³⁷, pedicled groin flaps, pedicled thigh flaps³⁸, pedicled myocutaneous flaps³⁹, free microsurgical forearm flaps⁴⁰ and miscellaneous free flaps⁴¹.

The creation of a phallus has been associated with multiple surgical problems, and efforts are ongoing to improve function and appearance. The older, insensate phallus shrived, and efforts to provide stiffness were associated with fistula formation and cutaneous erosions. Generally initial desire of female-to-male transsexuals is not a functional phallus, but to void while-standing in the men bathroom to elude this closure. Most patients express only a desire for a good appearance in swimsuits while only some transsexuals would like to be able to use the phallus sexually.

The ideal phalloplasty technique should: be a one-stage procedure; be cosmetically acceptable to both patient and partner; construct a neourethra to permit voiding whilst standing; have sufficient rigidity for vaginal penetration; have tactile and erogenous sensitivity; have minimal scarring in the donor area.

Since the first reported description of phalloplasty in 1936³³, a considerable variety of other techniques have been described, but, in our opinion, the gold standard technique for phalloplasty has not been described yet because each of them should be personalised depending on patient's desires or expectations and surgeon's skill.

The highest priority of most patients is the ability to urinate in public while standing, but this objective is the hardest to reach due the high complications rate. Distal urethra stenosis is the commonest urethral complication and this is due to ischemic necrosis of the most distal part of the labial tube. This would be particularly more common in patients who have a longer phallus and, therefore, need a longer labial tube constructed.

In case of patients who wish a functional phallus to void while-standing and to engage in sexual intercourse like a natural man, we think that the forearm free skin flap (Fig. 3)³⁰, which is soft, uniformly thin in subcutaneous tissue, and has a long vascular pedicle, seems to be an ideal donor.

Besides if patients expressed only a desire for a

Figure 3. The forearm free skin flap is completely isolated.

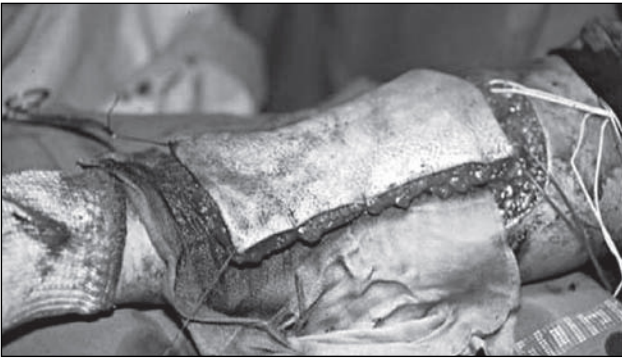
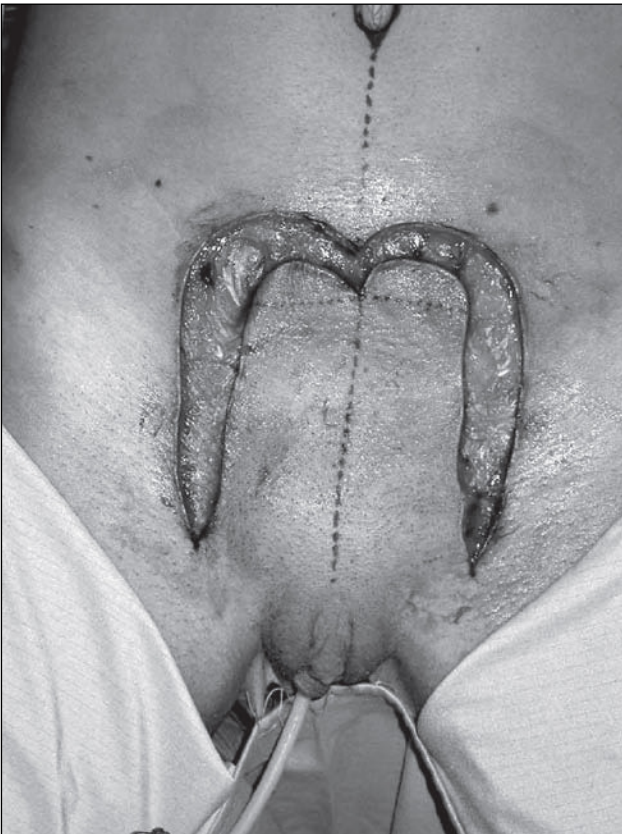
Figure 4. Pubic phalloplasty: the phallus is fashioned from a flap of anterior abdominal wall skin.



good appearance in swimsuits, pubic phalloplasty (Fig. 4)³⁷ is a simple and relatively quick procedure, leading to minimal scarring or disfigurements in the donor area. It is well accepted by the patient and his partner and occasionally rigid enough for penetrative sexual intercourse.

Reconstructive surgery for congenital and acquired penile curvature

Congenital penile curvature is caused by a disproportion between the corpora cavernosa and the

corpus spongiosum, resulting in dorsal or ventral curvature, or between the two corpora cavernosa, resulting in lateral curvature.

Penile curvature is usually evident only when the penis is in erection. Although the curvature is usually not severe enough to warrant surgical correction, in some cases it may lead to sexual dysfunction or interfere with intercourse due to difficulty in penetration.

Peyronie's disease (PD) is the most frequent cause of acquired penile curvature with an estimated prevalence of 0.4% in Caucasian men⁴².

PD is characterized by the onset of fibrous plaque inside the tunica albuginea of the penile corpora cavernosa that can cause pain and bending during the erection, making intercourse difficult. Evidence of the literature supports the autoimmune etiology of PD and suggests genetic and familial conditions, penile traumas, and a history of genital tract diseases as risk factors, but no definitive conclusions arise about the pathogenesis of the disease⁴³.

No medical therapy is fully effective, and surgery remains the gold standard in patients with severe deformity and/or erectile dysfunction who fail conservative measures. The indications for surgical correction of penile bending include severe curvature, narrowing, or indentation of more than 1 year's duration with sexual difficulty or partner discomfort because of deformity, and severe penile shortening⁴⁴.

Shortening procedures

These reconstructive techniques are performed on the convex surface of the penis at the site opposite to the penile plaque, are the easiest to perform, and require the least expertise. Patient selection is extremely important. Shortening procedures are most appropriate for patients with useful erection, adequate penile length, and without hourglass deformity. Nesbit first described the correction of congenital erectile deformities by shortening the opposite side of the penis by the excision of an ellipse of tunica albuginea. The Nesbit operation is performed by excising one or more ellipsoid wedge resections of the tunica albuginea on the side opposite to the curvature (Fig. 5a, b) and closing the albugineal defects with running absorbable sutures. The overall results are satisfactory, with a success rate of 82%. A literature review has confirmed these favourable results.

The most common complication of this procedure is loss of penile length. This complication does not preclude most men from having sexual intercourse. Other complications reported include erectile dys-

Figure 5a. Allis clamps are applied contiguously on the longer portion of the tunica albuginea until a complete straightening of the penis is achieved.

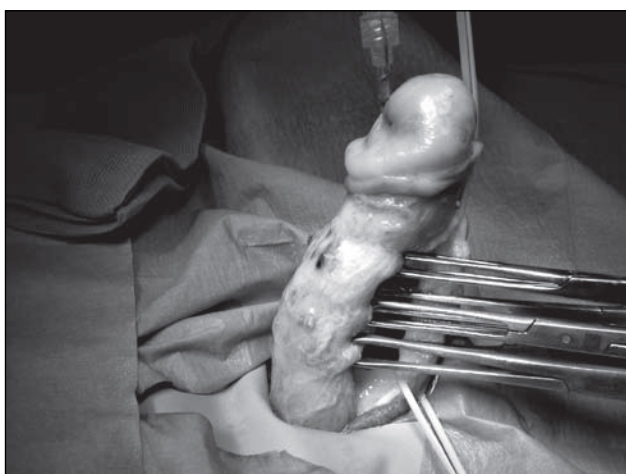
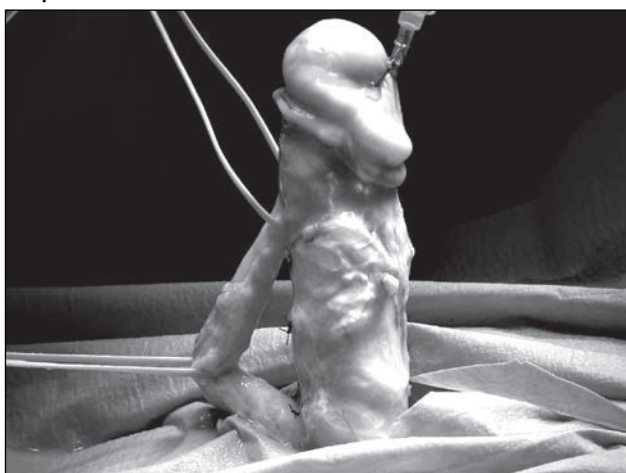


Figure 5b. After closing the albugineal defects with running absorbable sutures, artificial erection confirm the straightening of the penis.



function, penile hematoma, penile narrowing and urethral injury.

A modification of the Nesbit operation was described by Yachia in which, instead of removing an ellipse of tunica albuginea, a long longitudinal incision or multiple smaller longitudinal incisions are made in the area of maximum curvature of the corpora cavernosa (Fig. 6). These incisions are then closed horizontally to straighten the penis (Fig. 7), providing equal clinical success with less morbidity.

Many surgeons claim a high percentage of good results with this technique, reporting high satisfaction rates⁴⁵.

Wedge resection or incision of the tunica albuginea requires extensive dissection of the neurovascular bundle or corpus spongiosum. A simplified approach for correcting penile curvature is corporeal plication,

Figure 6. Multiple longitudinal incisions are made in the area of maximum curvature.

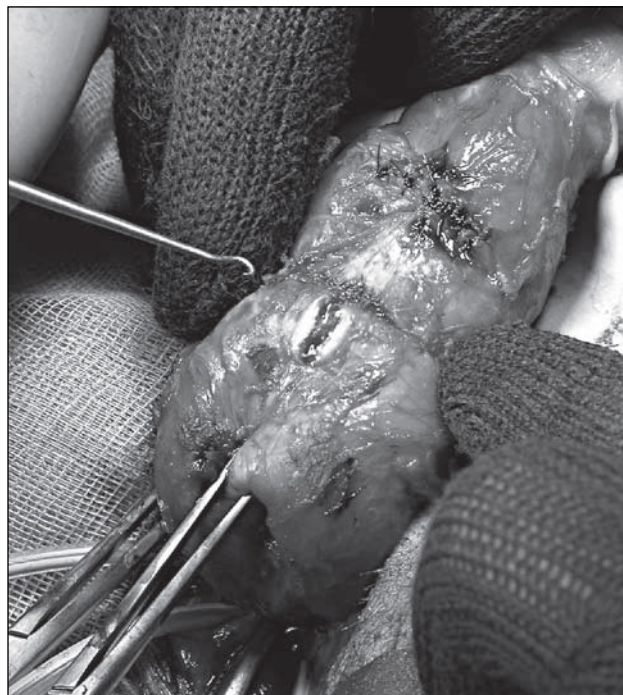
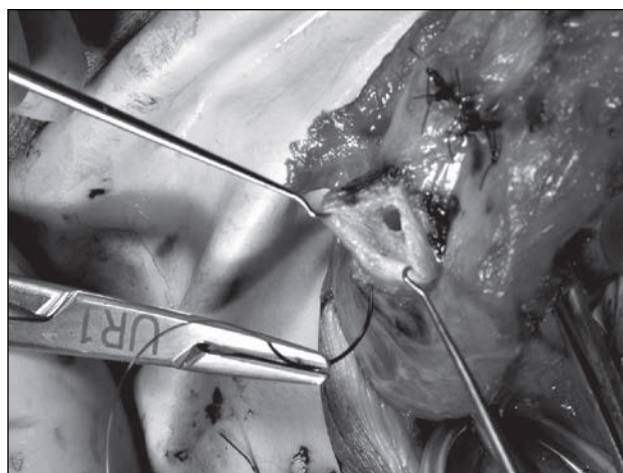

Figure 7. Incisions are closed horizontally.



in which two or three pairs of nonabsorbable longitudinal plication sutures are placed through the full thickness of the tunica albuginea on the side opposite the curvature. Some investigators describe high recurrence rates and poor results with prolonged follow up. The literature reports significant variation in the result, ranging from 38 to 100% satisfactory results⁴⁶.

Lengthening Procedures

These reconstructive techniques correct penile curvature while restoring the length of the curved shortened penis. Surgery is performed on the convex side

Figure 8a. Multiple tunical incisions are performed in order to increase the length of incised side.

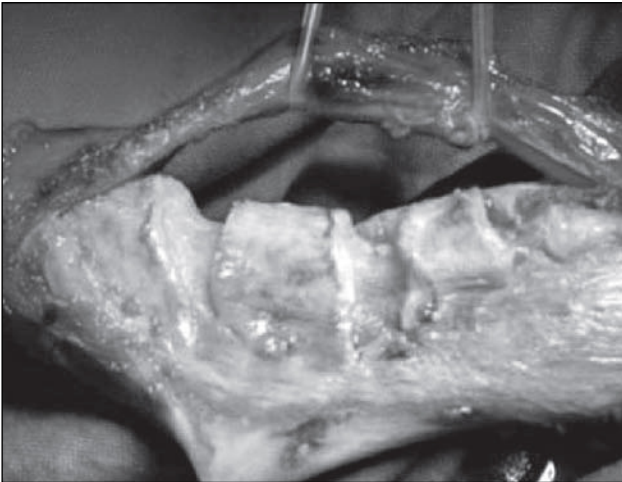
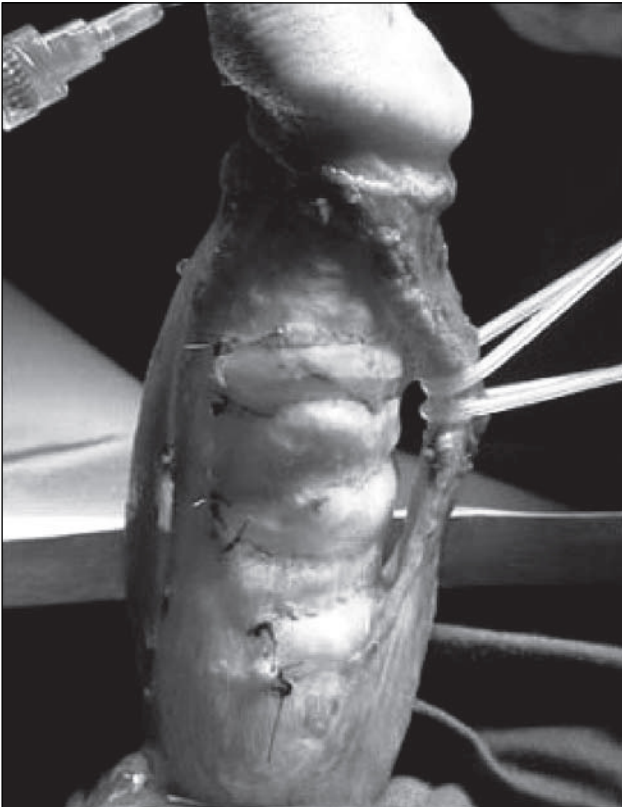


Figure 8b. Saphenous grafts are placed over the defect and sewn into place with a continuous 4-0 suture.



of the penis and requires plaque excision or incision with grafting. This procedure is indicated in case of severe curvature and shortened and deformed penis with narrowing or hourglass deformities.

Many autologous, cadaveric and synthetic materials have been described with different results for replacement of the tunica albuginea⁴⁷.

In the past excision of the plaque has been the standard approach. Unfortunately there was a great vari-

ability in the outcome of plaque excision. The most common problem was erectile dysfunction in case of removal of large areas of tunica albuginea and surrounding cavernosal tissue with the plaque⁴⁸.

In order to reduce the surgery-related traumatism to the erectile tissue, plaque incision and grafting was introduced, rather than excision (Fig. 8a, b).

Temporalis fascia graft was first described; nowadays a segment of the long saphenous vein is usually used⁴⁸ because it seems to give the best results⁴⁹. However the technique fails to lengthen the penis in many men and is also associated with an appreciable incidence of postoperative erectile dysfunction. Many surgeons also found that it was necessary to perform an additional plication procedure. This operation should be limited to men with marked foreshortening of the penis, obesity and good erectile function⁵⁰.

Conclusions

Although repair of the penis remains a great challenge, over the past decade penile surgery has continued to evolve. New surgical procedures and modifications of old procedures continue to improve penile reconstruction in order to offer a better quality of life and a better psychosexual outlook.

Bibliography

- 1 Busby JE, Pettaway CA. *What's new in the management of penile cancer?* *Curr Opin Urol* 2005;15:350-7.
- 2 Schoen EJ. *The relationship between circumcision and cancer of the penis.* *CA Cancer J Clin* 1991;41:306-9.
- 3 Bezerra AL, Lopes A, Landman G, Alencar GN, Torloni H, Villa LL. *Clinicopathologic features and human papillomavirus dna prevalence of warty and squamous cell carcinoma of the penis.* *Am J Surg Pathol* 2001;25:673-8.
- 4 Sufrin G, Huben R. *Benign and malignant lesions of the penis.* In: Gillenwater JY, editor. *Adult and pediatric urology.* 2nd edn. Chicago: Year Book Medical Publisher 1991, pp. 1643.
- 5 Narayana AS, Olney LE, Loening SA, Weimar GW, Culp DA. *Carcinoma of the penis: analysis of 219 cases.* *Cancer* 1982;49:2185-91.
- 6 Jariwala SK, Lambe S, Mammen KJ. *Surgical management of penile carcinoma: the primary lesion.* *BJU Int* 2006;98:917-8.
- 7 Brown CT, Minhas S, Ralph DJ. *Conservative surgery for penile cancer: subtotal glans excision without grafting.* *BJU Int* 2005;96:911-2.
- 8 Solsona E, Algaba F, Horenblas S, Pizzocaro G, Windahl T; European Association of Urology. *EAU guidelines on penile cancer.* *Eur Urol* 2004;46:1-8.
- 9 Hoffman MA, Renshaw AA, Loughlin KR. *Squamous cell carcinoma of the penis and microscopic pathologic margins: How much margin is needed for local cure?* *Cancer* 1999;85:1565-8.

- 10 McDougal WS. *Advances in the treatment of carcinoma of the penis*. Urology 2005;66(Suppl. 5):114-7.
- 11 Minhas S, Kayes O, Hegarty P, Kumar P, Freeman A, Ralph D. *What surgical resection margins are required to achieve oncological control in men with primary penile cancer?* BJU Int 2005;96:1040-3.
- 12 Smith Y, Hadway P, Biedrzycki O, Perry MJ, Corbishley C, Watkin NA. *Reconstructive surgery for invasive squamous carcinoma of the glans penis*. Eur Urol 2007;52:1179-85.
- 13 Melman A, Gingell JC. *The epidemiology and pathophysiology of erectile dysfunction*. J Urol 1999;161:5-11.
- 14 Riley AJ, Athanasiadis L. *Impotence and its non-surgical management*. Br J Clin Pract 1997;51:99-103.
- 15 Rao DS, Donatucci CF. *Vasculogenic impotence. Arterial and venous surgery*. Urol Clin North Am 2001;28:309-19.
- 16 Sharlip ID. *The role of vascular surgery in arteriogenic and combined arteriogenic and venogenic impotence*. Semin Urol 1990;8:129-37.
- 17 Wespes E, Wildschutz T, Roumeguere T, Schulman CC. *The place of surgery for vascular impotence in the third millennium*. J Urol 2003;170:1284-6.
- 18 Wespes E, Amar E, Hatzichristou D, Hatzimouratidis K, Montorsi F, Pryor J. *EAU Guidelines on erectile dysfunction: an update*. Eur Urol 2006;49: 806-15.
- 19 Goldstein I, Krane RJ. *Diagnosis and therapy of erectile dysfunction*. In: Walsh PC, Retlik AB, Stamey TA, Vaughn ED, editors. *Campbell's Urology*. 6th edn. Philadelphia: WB Saunders Co., 1998, pp. 3033-70.
- 20 Munarriz RM, Yan QG, Nehra A, Udelson D, Goldstein I. *Blunt trauma: the pathophysiology of hemodynamic injury leading to erectile dysfunction*. J Urol 1995;153:1831-40.
- 21 Rao DS, Donatucci CF. *Vasculogenic impotence. Arterial and venous surgery*. Urol Clin North Am 2001;28:309-19.
- 22 Schultheiss D, Truss MC, Becker AJ, Stief CG, Jonas U. *Long-term results following dorsal penile vein ligation in 126 patients with veno-occlusive dysfunction*. Int J Impot Res 1997;9:205-9.
- 23 Wespes E, Delcour C, Preserowitz L, Herbaut AG, Struyven J, Schulman C. *Impotence due to corporeal veno-occlusive dysfunction: long-term follow-up of venous surgery*. Eur Urol 1992;21:115-9.
- 24 Popken G, Katzenwadel A, Wetterauer U. *Long-term results of dorsal penile vein ligation for symptomatic treatment of erectile dysfunction*. Andrologia 1999;31(Suppl. 1):77-82.
- 25 Da Ros CT, Teloken C, Antonini CC, Sogari PR, Souto CA. *Long-term results of penile vein ligation for erectile dysfunction due to cavernous disease*. Tech Urol 2000;6:172-4.
- 26 Treiber U, Gilbert P. *Venous surgery in erectile dysfunction: a critical report on 116 patients*. Urology 1989;34:22-7.
- 27 Sasso F, Gulino G, Di Pinto A, Alcini E. *Should venous surgery be still proposed or neglected?* Int J Impot Res 1996;8:25-8.
- 28 Devine PC, Winslow BH, Jordan GH. *Reconstructive phallic surgery*. In: *Libertino A, editor. Pediatric and adult reconstructive urologic surgery*. 2nd edn. Baltimore: Williams & Wilkins 1987, pp. 552-66.
- 29 Chang TS, Hwang WY. *Forearm flap in one-stage reconstruction of the penis*. Plast Reconstr Surg, 1984;74:251-8.
- 30 Shenaq SM, Dinhl TA. *Total penile and urethral reconstruction with an expanded sensate lateral arm flap: case report*. J Reconstr Microsurg 1989;5:245-8.
- 31 Jordan GH, Gilbert DA, Winslow BH, Devine PC. *Single-stage phallic reconstruction*. World J Urol 1987;5:14.
- 32 Bogoras N. *Über die wolle plastische Wiederherstellung eines sum Koitus fahigen Penis (Penioplastica. totalis)*. Zentralbi Chir 1936;63:1271.
- 33 Maltz M. *Maltz technic*. In: *Evolution of Plastic Surgery*. New York: Froben Press 1946, pp. 278-9.
- 34 Hentz VR, Peari RM, Grossman JA, Wood MB, Cooney WP. *The radial forearm flap: a versatile source of composite tissue*. Ann Plast Surg 1987;19:485-98.
- 35 Snyder CC, Browne EZ. *Intersex problems and hermaphroditism*. In: *Converse JM, editor. Reconstructive plastic surgery: principles and procedures in correction, reconstruction and transplantation*. 2nd edn. Philadelphia: W.B. Saunders Co. 1977, pp. 3941-9.
- 36 Bouman FG. *The first step in phalloplasty in female transsexuals*. Plast Reconstr Surg 1987;79:662-4.
- 37 Pryor JP, Gill H. *Surgical considerations in 29 female to male transsexual patients*. Gender Dysphoria 1991;1:44.
- 38 McGregor IA, Jackson IT. *The groin flap*. Brit J Plast Surg 1972;25:3-16.
- 39 Kaplan I. *A rapid method for constructing a functional sensitive penis*. Brit J Plast Surg 1971;24:342-4.
- 40 Kao XS, Kao JH, Ho CL, Yang ZN, Shi HR. *One-stage reconstruction of the penis with free 5cm flap: report of three cases*. J Reconstr Microsurg 1984;1:149-53.
- 41 Gilbert DA, Horton CE, Terzis JK, Devine CJ Jr, Winslow BH, Devine PC. *New concepts in phallic reconstruction*. Ann Plast Surg 1987;18:128-36.
- 42 Lindsay MB, Schain DM, Grambsch P, Benson RC, Beard CM, Kurland LT. *The incidence of Peyronie's disease in Rochester, Minnesota, 1950 through 1984*. J Urol 1991;146:1007-9.
- 43 Sasso F, Gulino G, Falabella R, D'Addressi A, Sacco E, D'Onofrio A, et al. *Peyronie's disease: lights and shadows*. Urol Int 2007;78:1-9.
- 44 Gholami SS, Lue TF. *Peyronie's disease*. Urol Clin North Am 2001;28:377-90.
- 45 Daitch JA, Angermeier KW, Montague DK. *Modified corporoplasty for penile curvature: long-term results and patient satisfaction*. J Urol 1999;162:2006-9.
- 46 Schultheiss D, Meschi MR, Hagemann J, Truss MC, Stief CG, Jonas U. *Congenital and acquired penile deviation treated with the essed plication method*. Eur Urol 2000;38:167-71.
- 47 Kovac JR, Brock GB. *Surgical outcomes and patient satisfaction after dermal, pericardial, and small intestinal submucosal grafting for Peyronie's disease*. J Sex Med 2007;4:1500-8.
- 48 Kendirci M, Hellstrom WJ. *Critical analysis of surgery for Peyronie's disease*. Curr Opin Urol 2004;14:381-8.
- 49 Montorsi F, Salonia A, Maga T, Bua L, Guazzoni G, Barbieri L, et al. *Evidence based assessment of long-term results of plaque incision and vein grafting for Peyronie's disease*. J Urol. 2000;163:1704-8.
- 50 Pryor J, Akkus E, Alter G, Jordan G, Lebret T, Levine L, et al. *Peyronie's disease*. J Sex Med 2004;1:110-5.